

## A PROSPECTIVE STUDY ANALYSIS OF OUT COME OF DYNAMIC HIP SCREW (DHS) FIXATION FOR TROCHANTERIC FRACTURES OF FEMUR

Praveen Kumar<sup>1</sup>, Rahul Ranjan<sup>2</sup>, Ramashish Yadav<sup>2</sup>

<sup>1</sup>PG Student, Department of Orthopaedics, Darbhanga Medical College and Hospital, Darbhanga, Bihar, India

<sup>2</sup>Assistant Professor, Department of Orthopaedics, Darbhanga Medical College and Hospital, Darbhanga, Bihar, India

Received : 08/03/2023  
Received in revised form : 12/04/2023  
Accepted : 26/04/2023

**Keywords:**

Dynamic Hip Screw, Intertrochanteric fracture of femur.

Corresponding Author:

**Dr. Ramashish Yadav,**

Email: drramashishyadav123@gmail.com

DOI: 10.47009/jamp.2023.5.5.35

Source of Support: Nil,

Conflict of Interest: None declared

Int J Acad Med Pharm  
2023; 5(5); 166-169



### Abstract

**Background:** In recent decades the number of cases of proximal femoral fractures has dramatically increased. About one third of patients that sustain the fracture die within a year of the injury it also reduce life expectancy by an average of 1.8 years. **Materials and Methods:** This was a single site study, carried out at Darbhanga Medical College, Bihar between April 2022 and March 2023. Follow up was done for a maximum period of 18 months. Ethical clearance was obtained from the institute's ethical committee. There were 25 patients included in the study. **Result:** The mean age of the patients was 49.8 years but the individual age of the patients ranged from 22 to 82 years. Female preponderance for intertrochanteric fracture of femur. All the patients diagnosed with simple intertrochanteric fractures were fixed using dynamic hip screws and all reductions were achieved using closed methods. **Conclusion:** We observed that Dynamic Hip Screw when used for stable intertrochanteric fractures results in excellent to good functional outcomes however increasing age may cause a decline in functional scores.

## INTRODUCTION

In recent decades the number of cases of proximal femoral fractures has dramatically increased.<sup>[1]</sup> About one third of patients that sustain the fracture die within a year of the injury.<sup>[2]</sup> It also reduces life expectancy by an average of 1.8 years and one fifth of the rest of the patient's life is spent with dependency on long term care services,<sup>[3]</sup> while those who do survive beyond 6 months only fifty percent get back to their prefracture functional state.<sup>[4]</sup> Studies show that early fixation and mobilization reduces mortality in this group of patients.<sup>[5,6]</sup> Half of all hip fractures in elderly are intertrochanteric fractures more than 50% of which are of unstable variety.<sup>[8,9]</sup> About 5% of these fractures occur in the age group of 20 - 40 years while the rest of the 95% occur in the age group above 50 years indicating a bimodal pattern of occurrence. Because they occur in the elderly and in persons with low bone stock, they usually tend to be of unstable pattern.<sup>[10]</sup> These groups of patients owing to their age have multiple co morbidities and those in the age group of 40-50 years, who sustain these fractures are chronic alcoholics or have chronic illnesses.<sup>[11,12]</sup> Prolonged recumbence in these patients, according to Watson Jones, is due to malunion secondary to shortening and coxa Vera. This can be prevented by early intervention and fixation avoiding the deformity from

occurring and allowing early mobilization.<sup>[13,14]</sup> Intertrochanteric fractures' fixation began in the 1950s.<sup>[15,16]</sup> Extra medullary devices like DHS have proved to be good for stable fracture patterns.<sup>[17]</sup> One of our other published papers evaluating the outcomes and relevance of use of Proximal femoral nail in the treatment of unstable intertrochanteric fractures justified its use with regards to the functional outcomes it produced.<sup>[18]</sup>

Our aim in this study was to evaluate the results of use of DHS in our patient population with stable intertrochanteric fractures. DHS was considered the gold standard for the fixation of intertrochanteric fractures during the 80s and 90s. It consists of a large fragment side plate with a barrel at the plate's proximal end angled at varying degrees, ranging from 125 to 150 degrees. It consists of a 12.5 mm large diameter lag screw of lengths between 65 to 135 mm. They work on dynamic compression principle and have been found to fail due to screw cut out or plate pull off. Also, their allowance for controlled collapse, resulting in shortening and changes in abductor function, has driven the search for more stable treatment options.<sup>[19]</sup>

## MATERIALS AND METHODS

This was a single site study, carried out at Darbhanga Medical College and Hospital, Bihar between April

2022 and March 2023. Follow up was done for a maximum period of 18 months. Ethical clearance was obtained from the institute's ethical committee. There were 25 patients included in the study. All cases were diagnosed to have type 1 stable fractures as per Boyd and Griffin classification (1949).<sup>[20]</sup> Exclusion criteria comprise of patients who were unfit for surgery, those who did not give consent, those suffering from terminal illnesses or malignancies with short life expectancy, patients with cognitive disturbances, polytrauma and those who were non ambulant preinjury. Medical fitness for surgery was obtained and all were fixed using Dynamic hip screw by a single surgeon under subarachnoid block.

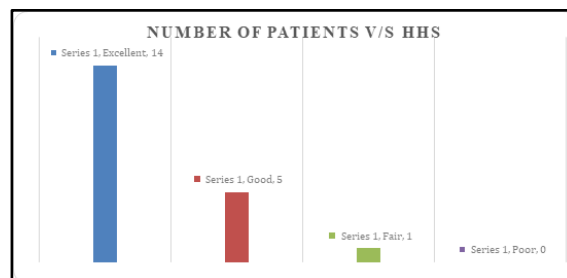
Patient was put on a traction with the fractured limb put on longitudinal traction and the normal limb placed in a well leg holder. Fracture reduction was done under fluoroscopic guidance and fixation started after good to satisfactory reduction, as per Baumgartner's criteria,<sup>[21]</sup> was obtained. A lateral incision for guide wire, lag screw and side plate insertion were used. A tip apex distance of < 25 mm was aimed at. Intravenous antibiotic coverage was started 30 minutes prior to the skin incision and continued for 5 days postoperatively. Knee mobilization, static quadriceps exercises were started from the first postoperative day. Follow up was carried out at regular intervals. Radiographic and functional assessment using Harris Hip score were carried out at each follow up. Quality of reduction was assessed using modified Baumgartner criteria.<sup>[21]</sup>

## RESULTS

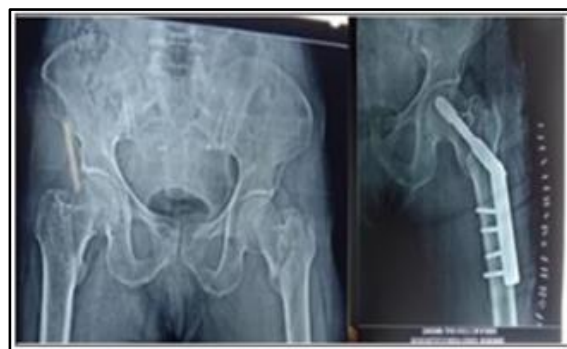The mean age of the patients was 49.8 years but the individual age of the patients ranged from 22 to 82 years. Out of 25 patients 11 patients were male (44%) and 14 patients were female (56%), showing a female preponderance for intertrochanteric fracture of femur. All the fractures classified as per Boyd and Griffin classification were type 1, stable fractures. All the patients diagnosed with simple intertrochanteric fractures were fixed using dynamic hip screws and all reductions were achieved using closed methods. Majority (82.3%) of the cases suffered trauma at home, especially the elderly patients, either by slipping in the bathroom or the stairwells. 79.2 % of the cases sustained trauma on the right side. The average duration from the day of admission to day of surgery was 4.1 days, longest delay being 6 days. There were no intra operative complications. The mean surgical time was 22 mins. Tolerated assisted weight bearing was begun from the 2<sup>nd</sup> to 10<sup>th</sup> postoperative day based on patient's pain tolerance.

Harris hip score was calculated. It ranged from 79.3 to 100 and mean score for 25 patients included in the study was 86.2 [Figure 1]. No mortality was reported during the follow up period of 18 months.

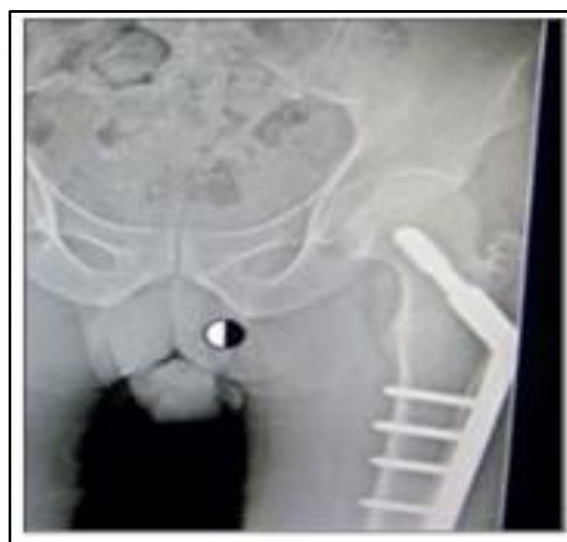[Table 1] Show the distribution of patients according to sex. Out of 25 patients 11 patients were male (44%) and 14 patients were female (56%), showing a female preponderance for intertrochanteric fracture of femur.



**Figure 1: Functional outcome in accordance to Harris Hip Score (HHS)**



**Figure 2: Preoperative x ray showing a type 1 intertrochanteric fracture. Alongside is the immediate postoperative X ray showing satisfactory reduction.**



**Figure 3: Follow up X-ray of the same cases at 18th month follow up. Complete radiological union of the fracture noted.**

**Table 1: Distribution of patients according to sex.**

Sex	Total no. of patients	Percentage
Male	11	44%

Female	14	56%
Total	25	100%

## DISCUSSION

Individuals of elderly age group are typically are predisposed to sustain intertrochanteric fractures.<sup>[22]</sup> Subjecting this group of population to surgical intervention is fraught with possibility of occurrence of complications due to multiple factors like reduced functional reserve, depressed immune system, multiple co morbid conditions and increased risk of anesthetic complications.<sup>[23]</sup> Dynamic hip screw is one of the most commonly used implants to fix intertrochanteric fractures.<sup>[24]</sup> It is preferred more for stable fractures than for unstable ones as the revision rates for unstable fractures are as high.<sup>[25,26]</sup> In the present study we fixed 20 cases of stable intertrochanteric fractures with Dynamic hip screws and sought to evaluate their functional outcomes. In our study, though there were no poor functional outcomes; we observed that with increasing age the functional outcomes declined as we could only achieve fair outcomes in patients of age group between 71 to 80. However, some studies found no direct influence of age on the rate of complications.<sup>[27]</sup>

We found no cases of avascular necrosis (AVN) of the femoral head whose risk according to Feng Yang et al. is elevated in patients with co morbid conditions like hypertension, Diabetes mellitus and ischemic heart disease which predisposes to atherosclerosis subsequently leading to AVN.<sup>[28]</sup> We did not observe any cases of non-union as described by Beam et al. though our patient population demographically was at risk for impaired bone healing.<sup>[29]</sup> In our study, 70% of patients had excellent, 25% had good while 5% had fair results. In comparison, Mardani Kivi et al. had 31.7% excellent, 63.3% good and 5% fair results.<sup>[30]</sup> Shetty et al. found 59.4% of their patients with unstable intertrochanteric fractures treated with DHS augmented with trochanteric stabilization plate had excellent to good result.<sup>[31]</sup> Barwar et al. observed 45.8% of their patients to have excellent results at the end of a year, having used DHS with a locking side plate to treat intertrochanteric fractures.<sup>[32]</sup> The higher percent of excellent results in this study could be attributed to the fact that, unlike the other mentioned studies; we included only stable fractures in this study as per the protocol of the institute.

## CONCLUSION

We observed that Dynamic Hip Screw when used for stable intertrochanteric fractures results in excellent to good functional outcomes however increasing age may cause a decline in functional scores.

## REFERENCES

1. Senohradski K, Markovic-Denic L, Lesic A, Bumbasirevic V, Bumbasirevic M. Trends in the incidence of hip fractures. *Osteoporos Int.* 2013; 24:1759-63.
2. Ngobeni RS. Mortality in elderly patients with intertrochanteric fractures: three years' experience. *SA Orthop J.* 2010; 9:55-60.
3. Braithwaite RS, Col NF, Wong JB. Estimating hip fracture morbidity, mortality and costs. *J Am Geriatr Soc.* 2003; 51:364-70.
4. Magaziner J, Fredman L, Hawkes W, Hebel JR, Zimmerman S, Orwig DL et al. Changes in functional status attributable to hip fracture: a comparison of hip fracture patients to community-dwelling aged. *Am J Epidemiol.* 2003; 157:1023-31.
5. Hallberg I, Bachrach-Lindstrom M, Hammerby S, Toss G, Ek AC. Health-related quality of life after vertebral or hip fracture: a seven-year follow-up study. *BMC MusculoskeletDisord.* 2009; 10:135.
6. Zlowodzki M, Tornetta P 3rd, Haidukewych G, Hanson BP, Petrisor B, Swiontkowski MF et al. Femoral neck fractures: evidence versus beliefs about predictors of outcome. *Orthopedics.* 2009; 32(4). Pii. orthosupersite.com/view.asp?rID = 38062.
7. Delee JC, Clanton To, Rockwood CA. Closed treatment of subtrochanteric fractures of femur in modified cast-brace. *J Bone and Joint Surgery Am.* 1981; 63:773-779.
8. Robert BW, James Heckman D, Charles Court Brown M. Rockwood and Green's Fractures in Adults, 2(6), 18271844.
9. David Lavelle G. Fractures and dislocations of the hip chapter-52 in Campbell's Operative Orthopaedics, eleventh edition, 3, 3237-3308.
10. Koval KJ, Aharonoff GB, Rokito AS, Lyon T, Zuckerman JD. Patients with femoral neck and intertrochanteric fractures: Are they the same? *ClinOrthop.* 1996; 330:166-172.
11. Gullberg B, Johnell O, Kanis JA. World-wide projections for hip fracture. *Osteoporos Int.* 1997; 7(5):407-413.
12. Robinson CM, Court-Brown CM, McQueen MM, Christie J. Hip Fractures in Adults Younger than 50 Years of Age. *ClinOrthopRelat Res.* 1995; (312):238-46.
13. Al-Yassari G, Langstaff RJ, Jones JW, Al-Lami M. The AO/ASIF proximal femoral nail (PFN) for the treatment of unstable trochanteric femoral fracture. *Injury.* 2002; 33:395-399.
14. SudhirBabhulkar S. Management of trochanteric fracture; *Indian journal of orthopaedics*, October. 2006; 40(4):210-218.
15. Schumpelick W, Jantzen PM. A new principle in the operative treatment of trochanteric fracture of the hip. *J Bone Joint Surg.* 1988; 70-A:1297-303.
16. Pugh WL. A self-adjusting nail plate for fractures about the hip joint. *J Bone Joint Surg.* 1955; 37-A:1085-93.
17. Davis TR, Sher JL, Horsman A, Simpson M, Porter BB, Checketts RG. Intertrochanteric femoral fractures: mechanical failures after internal fixation. *J Bone Joint Surg Br.* 1990; 72B:26-31.
18. Bhaskara K, Taranath N et al. Prospective study on the functional outcome of Intertrochanteric fractures treated with proximal femoral nail: is its use still relevant? *IJOTSS*, Dec – May. 2019 5(1).
19. Rockwood CA. Rockwood and Green's fractures in adult's 7th edition. Philadelphia, PA: Lippincott williams and Wilkins, 2085-2087.
20. Rockwood CA. Rockwood and Green's fractures in adults 7th edition. Philadelphia, PA: Lippincott williams and Wilkins, 2077.
21. Fogagnolo F, Kfuri Jr M, Paccola CAJ. Intramedullary fixation of pertrochanteric hip fractures with the short AOASIF proximal femoral nail *Arch Orthop Trauma Surg.* 2004; 124:31-37.
22. Webb LX. Proximal femoral fractures. *J South Orthop Assoc.* 2002; 11:203-12.

23. Roche JJW, Wenn RT, Sahota O, Moran CG. Effect of comorbidities and postoperative complications on mortality after hip fracture in elderly people: A prospective observational cohort study. *BMJ*. 2005; 331:1374.
24. Butler M, Forte ML, Joglekar SB, Swiontkowski MF, Kane RL. Evidence summary: systematic review of surgical treatments for geriatric hip fractures. *J Bone Joint Surg Am*. 2011; 93:1104-15.
25. Radford P, Needoff M, Webb JK. A prospective randomised comparison of the dynamic hip screw and the Gamma locking nail. *J Bone Joint Surg Br*. 1993; 75:789-93.
26. Willoughby R. Dynamic hip screw in the management of reverse obliquity intertrochanteric neck of femur fractures. *Injury*. 2005; 36:105-9.
27. Audigé L, Hanson B, Swiontkowski MF. Implant-related complications in the treatment of unstable intertrochanteric fractures: meta-analysis of dynamic crew-plate versus dynamic screw-intramedullary nail devices. *IntOrthop*. 2003; 27:197-203.
28. Feng Y, Yang SH, Xiao BJ, Xu WH, Ye SN, Xia T et al. Decreased in the number and function of circulation endothelial progenitor cells in patients with avascular necrosis of the femoral head. *Bone*. 2010; 46:32-40.
29. Beam HA, Parsons RJ, Lin SS. The effects of blood glucose control upon fracture healing in the BB Wistar rat with diabetes mellitus. *J Orthop Res*. 2002; 20:1210-6.
30. Mardani-Kivi M, MirbolookiJahromi SK, Rad MR. Fixation of intertrochanteric fractures: dynamic hip screw versus locking compression plate. *Trauma Mon*. 2021; 18:67.
31. Shetty A, Ballal A, Sadasivan AK, Hegde A. Dynamic hip screw with trochanteric stabilisation plate fixation of unstable intertrochanteric fractures: a prospective study of functional and radiological outcomes. *J ClinDiagn Res*. 2022; 10:06.
32. Barwar N, Meena S, Aggarwal SK, Garhwal P. Dynamic hip screw with locking side plate: a viable treatment option for intertrochanteric fracture. *Chin J Traumatol*. 2023; 17:88-92.